



Rev Mex Med Forense, 2018, 3(2):71-79

ISSN: 2448-8011

Human Identification through the study of osseous remains

Review Article

Edgar S. Gisbert-Monzón¹, Saúl Pantoja-Vacaflor²

Received: March 4, 2018, Accepted: Jun 4 2018, Published: August 15, 2018

¹ Forensic Physician, Forensic Physical Anthropology Expert IDIF, General Prosecutor of the Plurinational State of Bolivia, Member of the Scientific Expert Team

² Medical Pathologist, Hospital Obrero # 1, National Health Fund of La Paz - Bolivia, Department of Pathology (UMSA)

Corresponding author: Edgar S. Gisbert, esgmhuesos@gmail.com

SUMMARY

It is said that the forensic anthropology is the application of science to the judicial process. Daily there are osseous human remains in Bolivia, which up until the year 2003 were addressed by Forensic Medicine Services or other instances as the University or outside laboratories with poor results, so that since 2005 the first cases to the IDIF La Paz (Center pilot) were included, implementing the laboratory of forensic anthropology for the resolution of these cases in forensic matters, where an extreme challenge was the set of formulas and methods that are

more adapted to our population, which in essence is high Peruvian. This article presents suggestions concerning the methodology employed by the laboratory of forensic anthropology of the La Paz, Bolivia IDIF, for the examination of skeletal remains, human identification purposes, whose results are evidence for the Court, related to sex, biological age, descent, height, species, the minimum number of individuals and other aspects inherent to the death.

Keywords: *Osseous remains, tissue, analysis, human identification, anthropological methodology, ancestry.*

INTRODUCTION

The study of bone remains requested to the Institute of Forensic Investigations (IDIF), enters with a Judicial Order or Fiscal Requirement attached to their samples and evidence with its corresponding chain of custody; antemortem bioanthropological data will be obtained from relatives as well as information of crime scene (grave), date of disappearance and other aspects useful to contextualize the case.

The examination of bone remains begins with the preparation of the work environment consisting of physical and biological sterilization of the laboratory, examination tables and instruments, using UV light and solutions such as sodium hypochlorite and / or DG6, in order to avoid contamination of a sample that later will be used in Genetic Laboratory.

The preparation of the bone samples to be analyzed includes:

1. Counting of bony pieces
2. Reconstruction of the skeleton.
3. General photography and approach by segments
4. Bone scan
5. Cleaning the remains.

In relation to photography, it is suggested to take initial views with the remains of tissue and dirt, prior to the radiography and cleaning; after that, photographs with the neat skeleton (clean and reconstructed) will be taken.

Radiography is essential when establishing the pattern of trauma; it is suggested to take different angles of the skull, thorax, pelvis and any bone with suspected trauma; in situations where the skeleton presents clothing or remains in continuity with anatomical structures, it is

preferable to obtain the radiographic plates of the segments of interest without

modifying the skeleton (with clothes) (see figure 1).

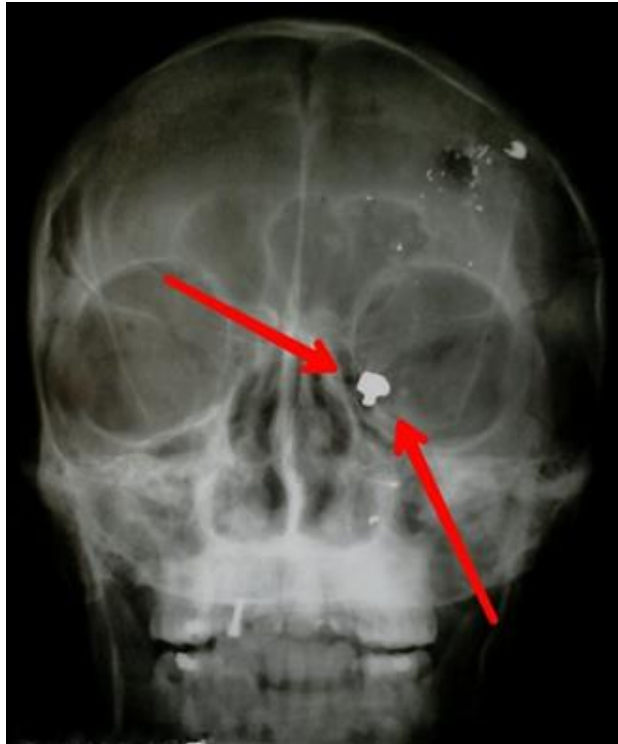

Fig. 1. X-ray of the skull. It shows a foreign body of metallic density (PAF) in the inner wall of the left orbit, anterior floor; note the presence of metal density splints in the calotte and upper left maxilla.

Cleaning of bones is recommended to be done by brushing; if there is dust or remains of fine earth and if the adhesions need to be removed with liquid, it is suggested to be made with tap water and free of solutions.

The expert study comprises (figures 2 and 3):

- Determination of Species and Minimum number of individuals (NMI).
- Anthropological examination: Age, Sex, Height, racial profile.

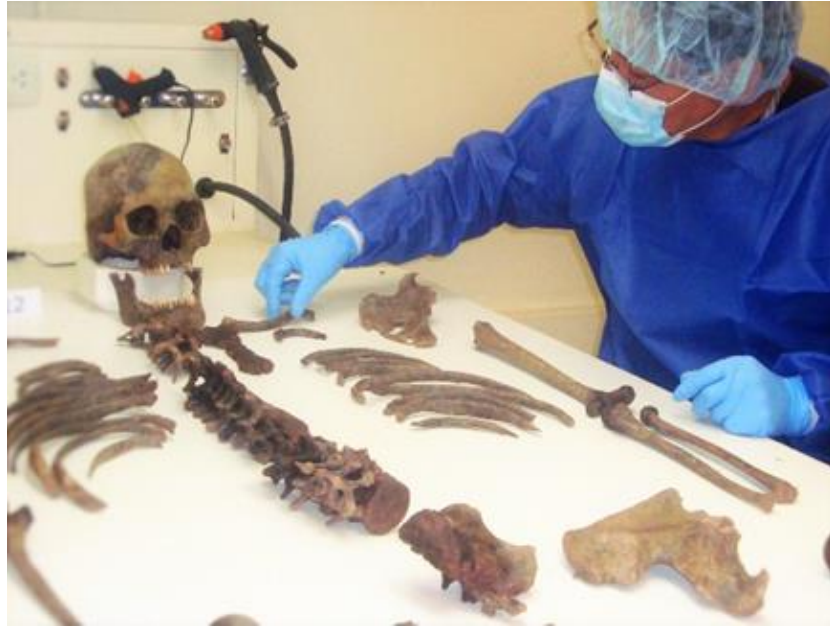

Fig. 2. Skeletal reconstruction, in the laboratory of Forensic Physics anthropology




Fig.3 Dental examination image, assessment by means of a magnification instrument with light source for translucency assessment.

The determination of ancestry consists in the observation of the morphological characteristics of bone remains such as: size, shape, texture, weight, cortical thickness, among other

analysable aspects that can be made by microscopy and measurements in diaphysis of long bones, where the marrow index in humans it is 0.45 to 0.48 mm (figure 4).

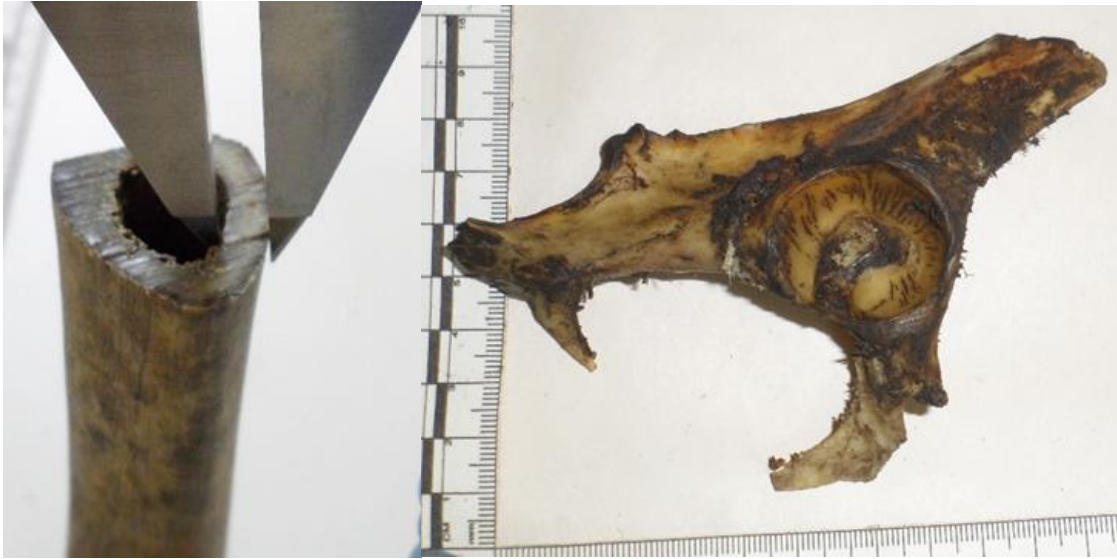

Fig. 4. On the left side, we appreciate the measurement of the diameter of the medullary canal; on the right side, wide obturator hole, transverse predominance, small acetabulum.

Sex estimation

In fresh, recent corpses, this determination can be made by observing the external and internal sexual organs. In the skeleton, the capital bone is the pelvis and the skull (table 1).

Diámetro vertical	VARON	MUJER
Cabeza de Fémur	> 45.5 mm	< 41.5 mm
Cabeza de Humero	> 47 mm	< 43 mm

Table 1. Metric determination of sex by diameter of femur or humerus

Ancestry estimation

Determination of the racial profile can be done by measuring cephalic indexes (table 2).

INDICES CEFÁLICOS.	Formula
Índice de altura craneal:	$\frac{\text{Alto del cráneo}}{\text{Largo del cráneo}} \times 100$
Índice de ancho:	$\frac{\text{Ancho del cráneo}}{\text{Largo del cráneo}} \times 100$
Índice orbitario:	$\frac{\text{Ancho de la órbita}}{\text{Largo de la órbita}} \times 100$
Índice Gnático:	$\frac{\text{Distancia de basión a huesos nasales}}{\text{Distancia de basión a procesos alveolares}} \times 100$
Índice nasal:	$\frac{\text{Ancho de la fosa nasal}}{\text{Altura de la fosa nasal}} \times 100$

Table 2. Cephalic indexes used for ancestry determination

Estimation of the racial affinity is made by observing the morphological characteristics of the skull (shape and size), as well as the configuration of the nasal passages, nasal spine, orbits, sutures, etc., the teeth also provide information on the racial profile, as well as the presence or absence of prognathism (teeth on shovel and the presence of Carabelli's tubercle).

Determination of age

For estimation of age of an individual, different methods are used, such as the study of development of bones (ossification), the study of skull, observing the degree of obliteration or closing of sutures (Mendly, Lovejoy 1985).

Determination of age by dental study, suggesting the Gustafson and Lamendin methods for adults and the Dermijian method for subadult subjects. Other proposed methods are: the study of the pubic symphysis with the method of Todd, the method of McKern and Stewart,

Gilbert and McKern; also the method of Brooks and Suchey, which consist of observing the morphology of the pubic symphysis; it can be applied the study of the surface of the atrial facet (morphology) and the facets of the fourth rib.

Estimation of Height

Determination of size or height is made by measuring the long bones of the lower or upper extremities in the osteometric table; it is advisable to use the formula of Genovés or Krogman-Iskan for this estimate because they are the most appropriate for our population.

The procedure concludes with obtaining biological samples for DNA for identification. The goal of the protocol of forensic anthropology is the human identification but it is suggested that samples for genetic comparison must be obtained by suitable personnel,

elaborating an act of sampling and preserving the Chain of Custody.

The expert study must be carried out in appropriate facilities for this purpose (Physical Anthropology laboratory) which, after a variable duration, will originate the Expert written report.

Complementary analysis

Regularly, assistance is requested from other areas, such as Entomology, which through the study of bacterial flora collaborates with the establishment of death data; Dentistry that confirms age and other aspects such as the biological and sociocultural profile; the other specialties that intervene in the process are Biology, which studies biological fluids, fibers, hair, nails, etc.; X-rays (images) that support the presence of traumatic injuries: fracture, fissure, solutions of continuity, absence of segments, presence of elements of different densities, metals or others; Criminalistics contributes to the cranio-photographic superimposition, record in the tasks in the scene of the event and geopositioning during the recovery of cadaveric remains and others.

CONCLUSION

The present article proposes a step-by-step methodology for the study of human skeletal remains, which could fundamentally be used by the personnel of Latinoamerica; It can be improved since renovations are permanently developing.

The Forensic Anthropology Laboratory of IDIF La Paz has been carrying out Expert Evaluations for more than a decade (2006 to 2017); consequently the methods and formulas

suggested in this paper are embodied in standardized work protocols.

REFERENCES

1. Antropología Forense – Identificación Humana Mediante el Análisis de restos óseos. Edgar S. Gisbert Monzon, Boletín Informativo BIM, Facultad de Ciencias Farmacéuticas y Bioquímicas UMSA, No 95/96/2014, DL 4-3-70-10. 5-6.
2. Estudio antropológico de restos óseos con fines de determinación de especie (humano o no humano). E. Gisbert Monzón. Revista Mexicana de Medicina forense y ciencias de la salud, vol 1, Nro1, 2016. 13-22.
3. Estudio forense de la vía respiratoria en cadáveres carbonizados., Gisbert-Monzón E., Pantoja-Vacaflor S. Revista Mexicana de Medicina forense y ciencias de la salud, vol 1, Nro1, 2016. 05-11.
4. Análisis genético de restos óseos.,Alcalá Espinoza E. Revista Mexicana de Medicina forense y ciencias de la salud, vol 1, Nro1, 2016, 23-31.
5. Guía de recomendaciones para la colección, envío de muestras – evidencias y exámenes forenses, IDIF. Antropología, 2006, 89-90.
6. Revista Señor Fiscal. Antropología y Genética Forense, Peritos del IDIF encuentran ADN en los restos carbonizados de una víctima de Femicidio. año 4, Nro 11, 2016.

7. Rodríguez Cuenca J, La antropología forense en la identificación humana. 1ª edición. Bogotá, D. C., Colombia, 2004.
8. Ubelaker, D. H.: "Human Skeletal Remains", Manuals on Archeology 2, Taraxacum, Washington, 1989...



**Revista Mexicana de Medicina Forense
y Ciencias de la Salud**